



ELSEVIER

Contents lists available at ScienceDirect

Foot & Ankle Surgery: Techniques, Reports & Cases

journal homepage: www.fastracjournal.org

Original Research

The accuracy of first metatarsophalangeal joint palpation guided injections. An arthrography cadaveric study


 Ian Reilly^{1,*}, Nachiappan Chockalingam², Roozbeh Naemi²
¹ Department of Podiatric Surgery, Northamptonshire Healthcare Foundation NHS Trust, Danetre Hospital, Daventry, Northamptonshire NN11 4DY, UK

² Centre for Biomechanics and Rehabilitation Technologies, Staffordshire University, Leek Road, Stoke on Trent ST4 2DF, UK

ARTICLE INFO

Keywords:

First metatarsophalangeal joint
Steroid injection
Hallux limitus
Hallux rigidus
Injection accuracy

ABSTRACT

Background: Injectable glucocorticoids are widely used in the management of foot pathology, in particular for the treatment of osteoarthritis of the great toe - hallux limitus/rigidus. Injections can be performed using anatomical (blind) guided methods or performed with needle placement aided by the use diagnostic imaging with ultrasound or fluoroscopy, with or without the use of contrast media.

Aim: Palpation and image guided injection techniques have been studied in other joints of the body but less so for the first metatarsophalangeal joint of the foot, where palpation guidance is commonly performed. The aim of this study was to investigate the injection accuracy of palpation guided injections of the first metatarsophalangeal joint in six cadaveric feet using radio-opaque contrast media.

Methods: The injection equipment consisted of a 2.5 ml Luer lock syringe and a 23-gauge needle used to inject iohexol (Omnipaque 300) into the first metatarsophalangeal joint in six cadaveric specimens. The needle was placed into the joint space by a single practitioner using palpation guidance. The contrast media was injected under live (cine) view without further movement or ingress of the needle. The injectate was considered accurate if the media coated the inside of the synovial membrane and/or outlined the joint shape.

Findings: Failure of technique was seen in one of six feet, and extravasation of contrast media beyond the joint margins noted in three out of six feet.

Conclusions: Further study on a large sample of live subjects using a variance of technique is required to expand the confidence of these findings but the high failure rate calls into question the confidence of palpation guided techniques for injection of the first metatarsophalangeal joint.

Introduction

Background

Injection therapy for joint pathology is one of the most common therapeutic interventions in musculoskeletal healthcare.¹ Most therapeutic injections into joints consist of a glucocorticoid, a local anaesthetic, or a combination of the two, and are widely used in the treatment of foot pathology, in particular for the treatment of osteoarthritis of the first metatarsophalangeal joint (1st MTP jt) - hallux limitus/rigidus.² Injections into the joint can be performed using anatomical (palpation-guided) guided methods³ or performed with needle placement aided by diagnostic imaging from ultrasound (US) or fluoroscopy, with or without the use of contrast media.^{4,5}

Arthrography

Injection of contrast media comes in two basic forms: injection via percutaneous needle access, such as direct arthrography, or injection via an indwelling catheter or tube, such as in cystography or sinography.⁶ Arthrography is the intra-articular (IA) injection of contrast media to improve the evaluation or visualisation of joint structures under imaging (i.e., outline the articular structures, and gives information on basic joint architecture) or for confirmation of needle placement prior to the intra articular delivery of medication(s).⁷

Aim

Palpation and image-guided techniques have been studied in other joints of the body but less so for the 1st MTP jt, where palpation

*Corresponding author.

E-mail address: ianreilly@nhs.net (I. Reilly).

<https://doi.org/10.1016/j.fastrc.2022.100219>

Received 23 April 2022; Revised 7 June 2022; Accepted 10 June 2022

guidance is commonly performed.⁸ Production of a best practice injection technique for the 1st MTP Jt by novice injectors has already been presented as part of this schema of work.³ The aim of this experiment was to investigate the accuracy of that technique and injectate placement using radio-opaque contrast media.

Methods

Ethical approval

The study was authorised by Innovation and Research Department, Northamptonshire Healthcare NHS Foundation Trust (NHFT) and approved by the Ethics Committee of Staffordshire University (ref: SPOR80004-2019-SPG2-2020-SPG1) as part of a professional doctorate programme.

Location of the study

The procedure room at Danetre Hospital, Daventry was used with access to handwashing and sharps disposal. The X-ray machine used was the InSight mini-C-arm fluoroscan (Holologic International). Personal protective equipment (PPE) consisted of a standard lead x-ray gown and thyroid protector, sterile gown gloves, and eye protection. The Principal Investigator (PI) was Ian Reilly, with assistance from a Podiatric Surgery team member for additional photography. The PI is a Radiation Protection Supervisor (RPS) with authority and responsibility to direct and expose radiographic images. Standard safety precautions were followed, as per the (Northamptonshire Healthcare Foundation NHS Trust (NHFT) C-Arm protocol.

Cadaveric specimens

A total of six cadaveric feet from six individual donors were used for this investigation, which was the maximum number that were available at the time of the study. All cadaveric feet were anonymous, fresh-frozen specimens, thawed overnight, and obtained from the Procedural Skills Laboratory at Nottingham City Hospital (NCH), and delivered via anatomy technologists to the NHFT Department of Podiatric Surgery, Danetre Hospital. The anatomy technologists were responsible for the transporting, safety, and safe return of all cadavers and at all times the

feet were the responsibility of the NCH anatomical team. The specimens were noted to be free from major deformity, trauma, or surgical changes. Three feet were right-sided, three were left-sided.

Procedure

A green (21-gauge needle) was used to draw up the injectate into a 2.5 ml Luer lock syringe, and a blue (23-gauge needle) needle to inject the contrast media. The injectate was iohexol [N,N-Bis(2,3-dihydroxypropyl)-5-[N-(2,3-dihydroxypropyl)-acetamido]-2,4,6-triiodoisophthalamide], a non-ionic, water-soluble radiographic contrast medium, with a molecular weight of 821.14 and iodine content 46.36%. nn (Omnipaque, GE Healthcare AS, Buckinghamshire, UK). Immediately prior to the study six identical syringes were prepared with 2.5 ml of Omnipaque 300.

All injections were performed by the PI using the following sequence:

1. The PI placed a blue, 23-gauge hypodermic needle in the 1st MTP jt in six cadaveric specimens using a standard palpation guided technique,
2. A pre-injection anterior-posterior (AP) x-ray was taken of the foot but with no change in position or further ingress of the needle (see Fig. 1),
3. 2 ml of iohexol was injected into the joint space under live (cine) view ensuring safe distancing of the PI from the x-ray beam,
4. Following each injection, the foot was x-rayed in the AP and lateral (LAT) planes to confirm the location of contrast media placement (see Fig. 2),
5. The injectate was considered accurate if the contrast media coated the inside of the synovial membrane and/or outlined the joint shape,
6. The contrast media was considered inaccurate if the dye did not coat the inside of the synovial membrane or outline the joint shape,
7. Each injection/x-ray sequence took between 3 and 5 min,
8. All X-rays were stored on secure NHS server for further assessment,
9. The results were tabulated and subject to further analysis (see Table 1).

See supplementary video material.

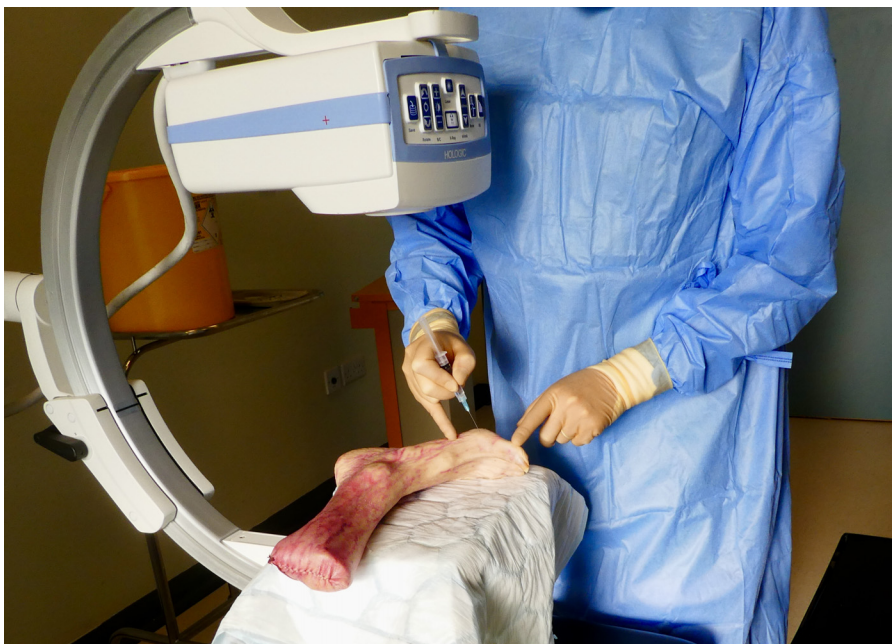

Fig. 1. Needle placement in the 1st MTP jt prior to X-ray.

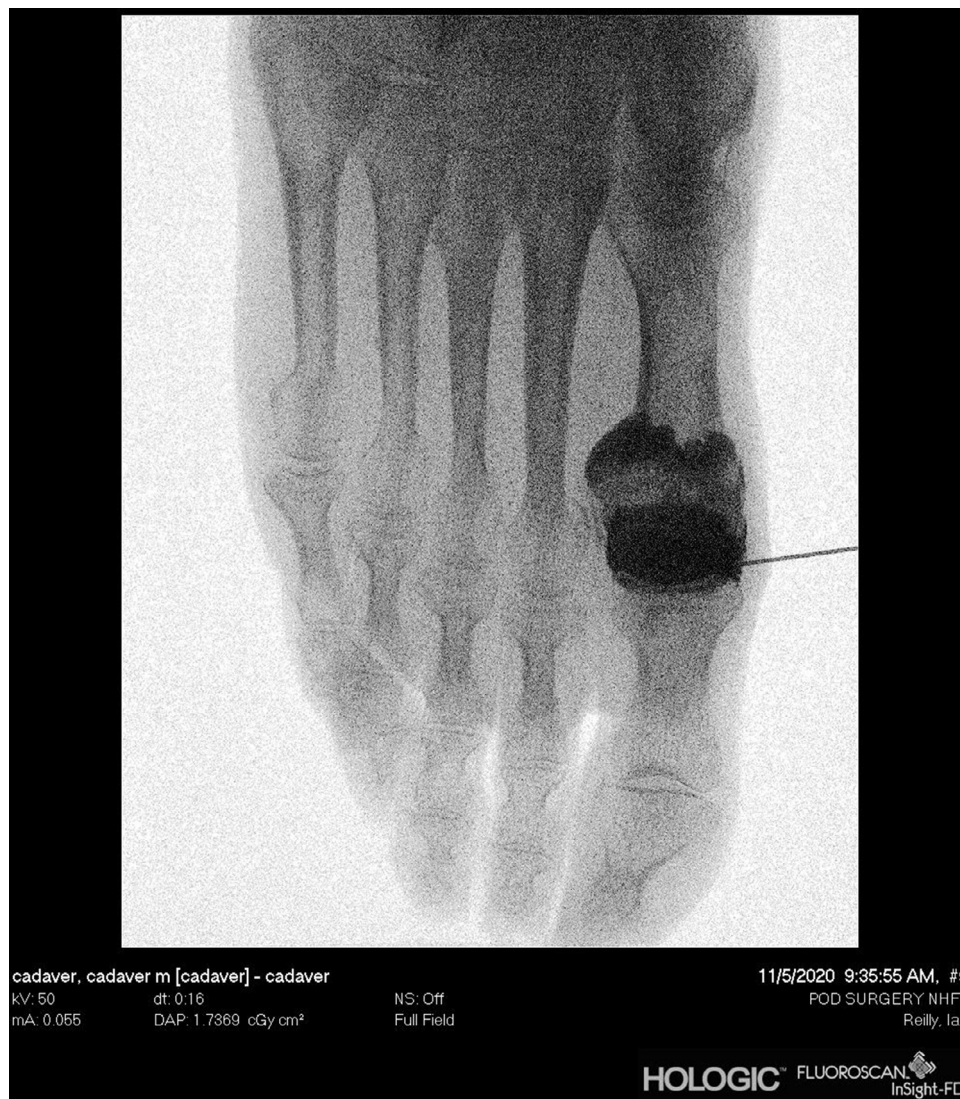

Fig. 2. Needle placement in the 1st MTP jt (specimen 1) post infiltration.

Results

The results are at Table 1 (see supplementary images). An extra, pre-infiltration, lateral x-ray was taken of specimen 1 only, prior to injection of the contrast media. No lateral view was taken for specimen 2 owing

Table 1
Results of contrast media placement.

Specimen	Accurate?	Leakage	Remarks
1	Yes	No	One extra pre-injection lateral X-ray view demonstrating good needle placement prior to injection
2	No	NA	Significant extra-capsular leakage medially, and proximally via a digital vessel; no lateral view taken
3	Yes	Yes	Accurate injection but slight leakage of dye plantar-proximally
4	Yes	Yes	Accurate injection but moderate leakage dorso-medial and proximally
5	Yes	Yes	Accurate injection but slight leakage of dye plantar-proximally
6	Yes	No	Dorsal joint mouse seen on encircled with dye on lateral view but within synovial membrane

to the surprising failure in technique causing the PI to omit this step (see Fig. 3). Five out of the six injections were accurate with the contrast media coating the inside of the synovial capsule. However, three of five accurate injections (specimens 3, 4 and 5) showed some extravasation of the contrast media beyond the joint space: two plantar-proximally and one dorso-medially and proximally (see Fig. 4).

The cadavers were subsequently used as part of a cadaveric surgery dissection course for podiatric surgery students. On specimen 1, following dissection of the soft tissues and subcutaneous layer away from the joint capsule, a 1.0 mm Kirschner (K) wire was inserted into the joint using the standard palpation guided technique. With minimal extra advancement of the K-wire, the tip punctured and exited the capsule dorso-laterally (see Fig. 5). A wider discussion around technical failure will be the subject of a subsequent article.

Discussion

Koski et al.⁹ state that palpation guided injection of joints and soft tissues is an important clinical skill used in everyday work by clinicians in several speciality fields. Naylor et al.⁸ had 18 emergency medicine residents perform four US and four landmark (LM) guided aspirations each of 1st MTP jt simulated effusions in fresh-frozen cadavers. A total of 144 joint aspirations were attempted: 72 by US and 72 by LM guidance. In

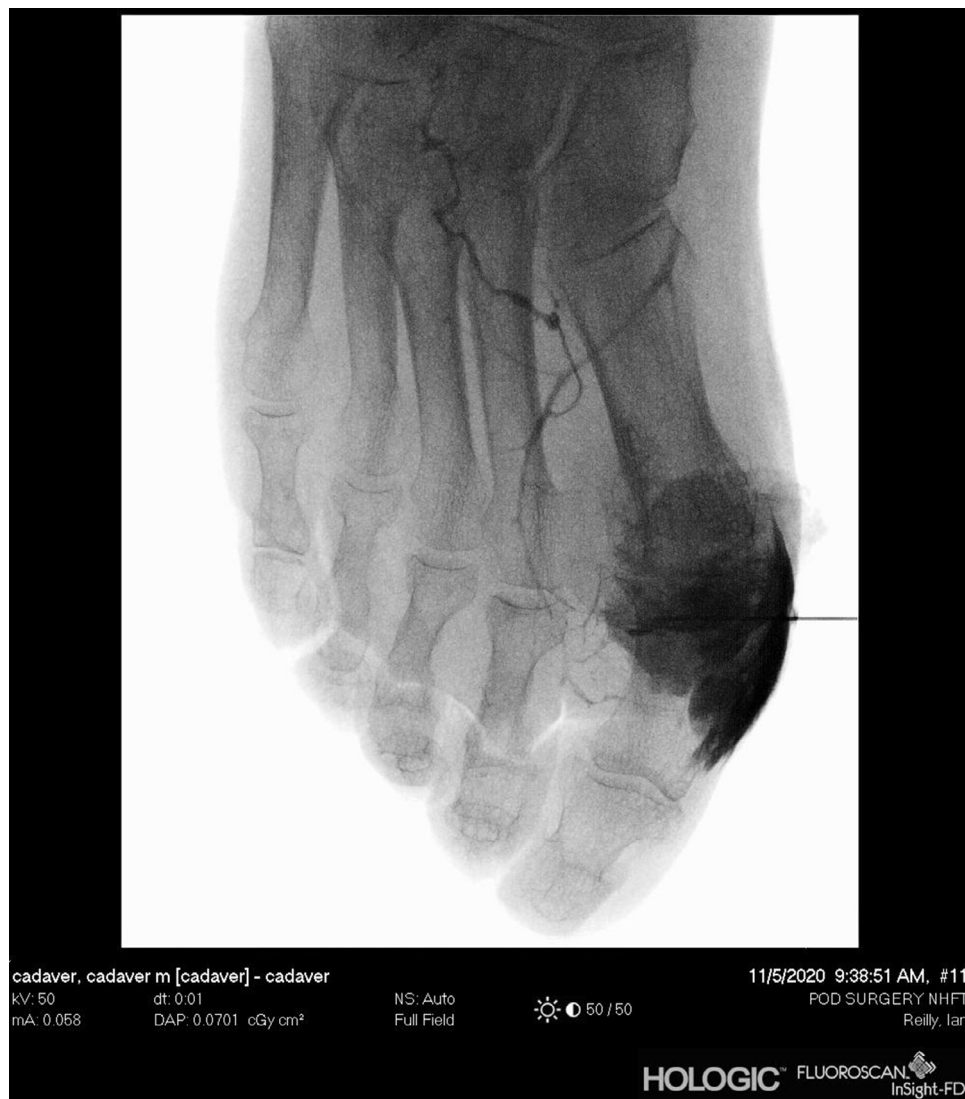

Fig. 3. Inaccrurate injection and leakage into local vessels (specimen 2).

their study, US did not prove superior to LM for first-pass aspiration of 1st MTP jt effusions. The PI was expecting to see 100% accurate injections in this study and therefore the complete failure of technique in specimen two was surprising. Further work is now planned to identify the reasons for - and management of - injection technique failure. Three of the five accurate injections had extra-capsular leakage which may predispose to complications such as atrophy and tendon rupture. Further, the live (cine) view demonstrates the contrast media infiltrating the medial tissues then intravenously entering one of the digital vessels and coursing proximally. This has implications for the under-reported risk of accidental intravenous injection. Regrading contrast media, Wang et al.¹⁰ note that most patients in whom extravasations of nonionic iodinated contrast medium occur rarely result in moderate or severe adverse effects but McAlister and Palmer¹¹ note that an acute local inflammatory response from contrast media may not peak until 24 to 48 h post procedure.

Derian et al.¹² state that smaller joints, such as the first carpometacarpal joint (CMC) are often affected by degenerative joint conditions that may benefit from therapeutic injections. They hypothesised that image guidance may be useful for accurate needle placement in these smaller joints but in an ultrasound vs palpation guided latex dye injection cadaveric study of the 1st CMC jt, they found no difference between the two methods. However, injectate placement accuracy - judged on a

four-point scale after dissection of the joint - found that most of the injections (59.7%) were 50%, or less, accurate.

Pollard et al.¹³ investigated the accuracy of IA injection of the basal thumb joint and to determine the rate of soft-tissue extravasation of injected material in successful IA injection. The authors injected 30 cadaveric hands with radiopaque dye - with fluoroscopy-guided needle placement in 8 specimens - and then used fluoroscopy to check injection accuracy. The results were recorded depending on the location of the injected dye under fluoroscopic examination. The rates of IA accuracy and soft-tissue extravasation for successful IA injections were 100 and 25% for the fluoroscopy guided group and 81.8 and 33% for the “blind” group. The authors discuss that this is a relatively high soft tissue extravasation rate for successful IA injection with the implications for drug extravasation into the surrounding extra-articular space presumed to be similar to those cited for failed needle placement. The authors also recommend injecting a drug at an appropriate volume. In their study, 0.2–0.5 mL were injected; they note that a palpable endpoint was difficult to detect but they suggest that forcing excess fluid into the joint space may induce a painfully distended capsule and that care must be exercised during injections to prevent excessive internal pressurization of the capsule. The authors accept the shortcomings of their study viz using preserved cadaveric specimens for injection where surface

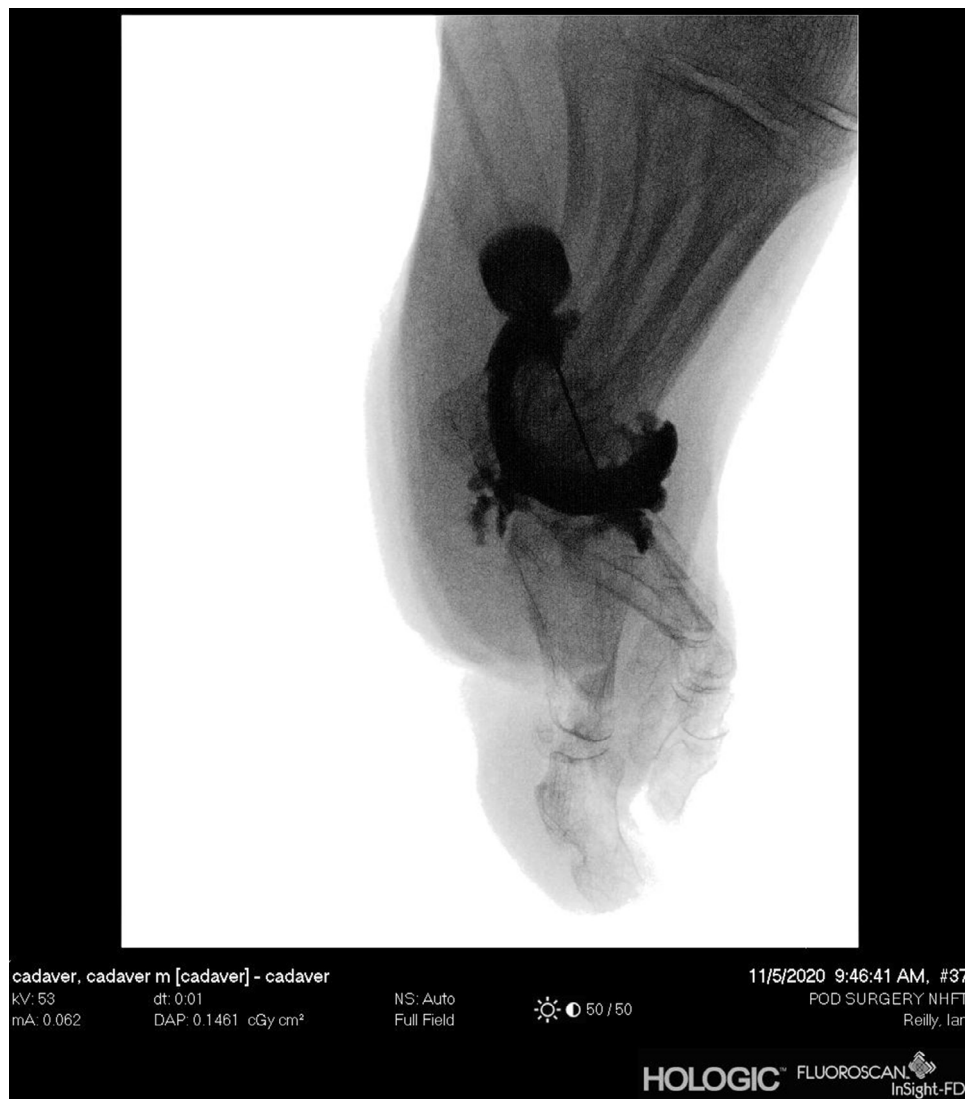

Fig. 4. Extra-articular leakage of injectate (specimen 5).

anatomy (and joint mobility) is more difficult to identify in stiff, embalmed specimens.

The local pathological changes and the experience of the clinician are also relevant. Heidari et al.¹⁴ found that the presence of pathologic changes reduces the rate of successful IA puncture, but that the overall frequency of successful IA injections can be improved through experience and the use of imaging. In their study a total of 106 cadaveric 1st MTP jts were injected with a methylene blue solution and then dissected to distinguish IA from periarticular injections. To evaluate the importance of experience, 38 injections were performed by a student, 38 by a trained resident, and 30 by an experienced surgeon. In the second part of the study, the authors examined the relation of pathologic findings of the MTP jt and the accuracy of IA injection. The overall rate of unintentional periarticular injections was low (9.4%; 10 of 106 joints). The student achieved a successful IA injection in 86.8% of joints (33 of 38), the resident in 92.1% (35 of 38), and the specialist in 93.3% (28 of 30). The number of extra-articular injections increased significantly with the presence of deformity (hallux valgus) or osteoarthritis of the 1st MTP jt.

Curtiss et al.¹⁵ found that the accuracy of supero-lateral, palpation-guided knee injections were significantly influenced by experience, with a less-experienced investigator demonstrating an accuracy rate of only 55% compared to a more experienced investigator demonstrating an

accuracy rate of 100%. At the time of the investigation, the senior author had 19 years of experience in injection therapy of the foot and ankle, including 14 years' experience in teaching injection techniques to podiatrists and trainee podiatric surgeons, nationally and internationally. The overall implication of our study is therefore that palpation guided injections of the 1st MTP jt has a significant failure rate, in this series despite the experience of the PI. This calls into question the accuracy of palpation guidance for the 1st MTP Jt.

Multiple systematic reviews by confirm that injection accuracy is improved with the use of US guidance over palpation-guidance. Over advancement of the needle into and out of the joint could be one reason for technique failure. Compounding the failure could be the length of the needle. Typically, the senior author recommends a 1¼ inch 23-gauge (blue) needle as the standard for 1st MTP jt injections. A shorter needle, for instance the ¾ inch 25-gauge (orange) needle might be less prone to 'overshooting the target'. These factors will be discussed in greater detail in a subsequent paper.

This study had several limitations that warrant discussion. The first consideration is the sample size. Only six specimens were available at the time of the study, which was insufficient to carry out statistical analysis. Consideration was given to performing a post-hoc power calculation but as the main effort of this study was to look at needle accuracy, and this was

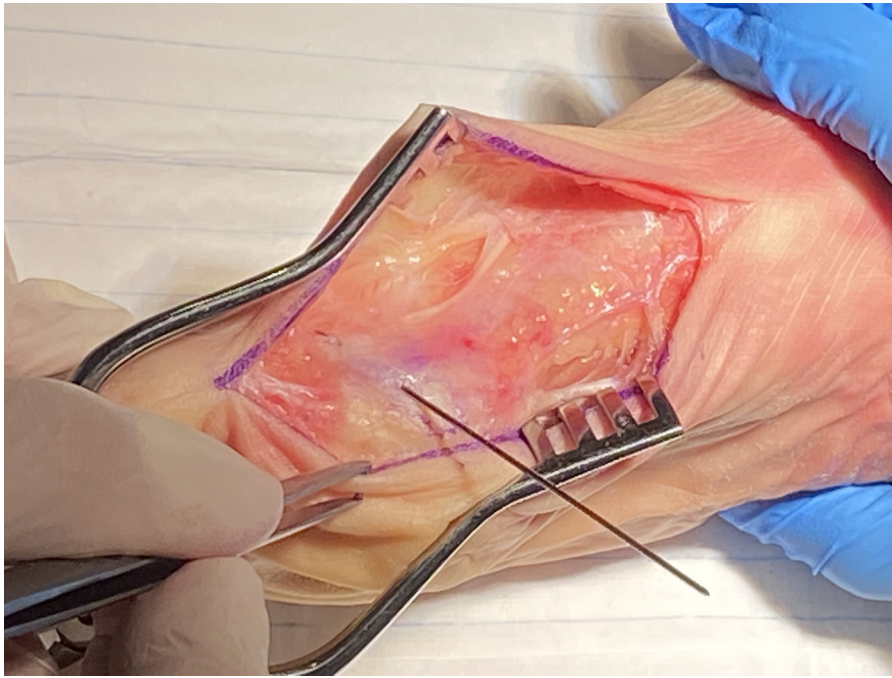


Fig. 5. Needle placement in the 1st MTP jt.

therefore discounted. Future studies would benefit not only from having a larger sample size and performed using live subjects with confirmed metatarsal phalangeal joint pathology (rather than cadaver specimens). Use of fresh frozen over embalmed specimens was considered to be as close to a realistic clinical scenario as possible, and injection equipment used was exactly that as used by the author in clinical practice but as Pollard et al.¹³ (and other authors) state in their studies, clinicians may wish to exercise caution when extrapolating cadaveric data into clinical populations.

Conclusion

The accuracy of palpation-guided injections of the 1st MTP jt was assessed in an arthrography cadaveric study. In this study there was a complete failure of technique in one of six specimens and extra-capsular leakage in three out of six specimens. Further work is required to identify the reasons for - and management of - injection technique failure.

Ethics approval and consent to participate

Ethical approval was sought and received from Staffordshire University Ethics committee.

Consent for publication

Not applicable.

Availability of data and material

Data for this paper is available on request.

Funding

This research did not receive any grant from funding agencies in the public, commercial, or not-for-profit sectors.

Declaration of Competing Interest

The authors have no competing interests to declare.

CRediT authorship contribution statement

Ian Reilly: Conceptualization, Methodology, Visualization, Investigation, Writing – original draft, Writing – review & editing. **Nachiapan Chockalingam:** Visualization, Writing – review & editing. **Roosbeh Naemi:** Visualization, Writing – review & editing.

Acknowledgments

The authors would like to thank the technicians and staff of the Anatomy Laboratory of Nottingham City Hospital who provided the cadaveric materials. Contributions and support from Sharon Taylor, Clinical Assistant in Podiatric Surgery, NHFT, for help with the cadaveric examinations is also acknowledged.

Supplementary materials

Supplementary material associated with this article can be found in the online version at [doi:10.1016/j.fastrc.2022.100219](https://doi.org/10.1016/j.fastrc.2022.100219).

References

1. Wittich CM, Ficalora RD, Mason TG, Beckman TJ. Musculoskeletal injection: concise review for clinicians. In: *Proceedings of the Mayo Clinic*. 84, 2009. <https://doi.org/10.4065/84.9.831>.
2. Reilly IN, Bromley G, Flanagan G. A systematic review of injectable corticosteroid for osteoarthritis of the first metatarsophalangeal joint. *Foot Ankle Online J*. 2020;13(3). [accessed 3 Jan 2021] Available from; <http://faoj.org/2020/09/30/a-systematic-review-of-injectable-corticosteroid-for-osteoarthritis-of-the-first-metatarsophalangeal-joint/>.
3. Reilly I. Palpation-guided intra-articular injection of the first metatarsophalangeal joint: injection technique and safe practice for novice practitioners. *SN Compr Clin Med*. 2021. <https://doi.org/10.1007/s42399-020-00719-w>.
4. Hansford BG, Mills MK, Hanrahan CJ, Yablon CM. Pearls and pitfalls of fluoroscopic-guided foot and ankle injections: what the radiologist needs to know. *Skeletal Radiology*. 48. Springer Verlag; 2019:1661–1674. <https://doi.org/10.1007/s00256-019-03226-9>.
5. Sofka CM, Adler RS. Ultrasound-guided interventions in the foot and ankle. *Semin Musculoskelet Radiol*. 2002;6(2). <https://doi.org/10.1055/s-2002-32362>.
6. Pasternak JJ, Williamson EE. Clinical pharmacology, uses, and adverse reactions of iodinated contrast agents: a primer for the non-radiologist. In: *Proceedings of the Mayo Clinic*. 87, Elsevier Ltd; 2012:390–402. <https://doi.org/10.1016/j.mayocp.2012.01.012>.
7. Masala S, Fiori R, Bartolucci DA, et al. Diagnostic and therapeutic joint injections. *Semin Interv Radiol*. 2010;27(2):160–171. <https://doi.org/10.1055/s-0030-1253514>.

8. Naylor JF, Dekay KB, Donham BP, Hall BT. Ultrasound versus landmarks for great toe arthrocentesis. *Mil Med.* 2017;182:216–221. <https://doi.org/10.7205/MILMED-D-16-00055>.
9. Koski JM, Hermunen HS, Kilponen VM, Saarakkala SJ, Hakulinen UK, Heikkinen JO. Verification of palpation-guided intra-articular injections using glucocorticoid-air-saline mixture and ultrasound imaging (GAS-graphy). *Clin Exp Rheumatol.* 2006;24(3):247–252. Available from: <https://www.researchgate.net/publication/6916476>.
10. Wang CL, Cohan RH, Ellis JH, Adusumilli S, Dunnick NR. Frequency, management, and outcome of extravasation of nonionic iodinated contrast medium in 69 657 intravenous injections. *Radiology.* 2007;243(1):80–87. <https://doi.org/10.1148/radiol.2431060554>.
11. McAlister WH, Palmer K. The histologic effects of four commonly used media for excretory urography and an attempt to modify the responses. *Radiology.* 1971;99(3):511–519. <https://doi.org/10.1148/99.3.511>.
12. Derian A, Amundson J, Abi-Aad K, Vasquez-Duarte R, Johnson-Greene D. Accuracy of ultrasound-guided versus palpation-based carpometacarpal joint injections: a randomized pilot study in cadavers. *Ultrasound.* 2018;26(4):245–250. <https://doi.org/10.1177/1742271X18789711>.
13. Pollard MA, Cermack MB, Buck WR, Williams DP. Accuracy of injection into the basal joint of the thumb. *Am J Orthop.* 2007;36(4):204–206.
14. Heidari N, Kraus T, Fischerauer S, Tesch N, Weinberg A. Do the presence of pathologic changes and the level of operator experience alter the rate of intra-articular injection of the first metatarsophalangeal joint? A cadaver study. *J Am Podiatr Med Assoc.* 2013;103(3):204–207. <https://doi.org/10.7547/1030204>.
15. Curtiss HM, Finnoff JT, Peck E, Hollman J, Muir J, Smith J. Accuracy of ultrasound-guided and palpation-guided knee injections by an experienced and less-experienced injector using a superolateral approach: a cadaveric study. *PM and R.* 2011;3(6):507–515. <https://doi.org/10.1016/j.pmrj.2011.02.020>.